

THE STATE OF CHILDREN MASTICATORY MUSCLES WITH DENTITION DEFECTS IN THE FRONTAL AREA AND NARROWING OF DENTAL ARCHES IN THE TRANSVERSE PLANE

Svitlana Savonik

Postgraduate Student at the Department of Orthopedic Dentistry and Orthodontics,
Private Educational Institution “Kyiv Medical University”, Ukraine
e-mail: dr.lanasavonik@gmail.com, orcid.org/0000-0003-3865-327X

Summary

Orthopedic and orthodontic treatment of 49 patients aged 6 to 17 years with dentition defects in the frontal area was examined and performed to conduct and determine the state of the masticatory muscles in children with dentition defects. Patients were divided into two groups depending on the period of formation of the dento-maxillaire system and each of the groups was divided into two subgroups depending on the method of treatment and the mechanism of fixation of the orthodontic appliance in the oral cavity. When comparing the indicators between groups I A and I B, we can state that there were more qualitative and dynamic changes in electromyographic indicators in children of group I B than group I A. When comparing the data received after orthopedic and orthodontic treatment of children in group II, we can state that quantitative and qualitative indicators of electromyography for group II B were better than those of children in group II A. In children who were treated with removable appliances, these indicators improved, but remained at a worse level than in those treated with non-removable appliances.

Keywords: dentition defect, electromyography of the masticatory muscles, orthodontic treatment.

DOI <https://doi.org/10.23856/4336>

1. Introduction

Nowadays, the requirements for the provision of dental care to the population, and in particular to children, are being increased. In turn, the requirements for diagnostic equipment, which provides a comprehensive assessment of the functional state of the dento-maxillaire system are being increased as well (*Iezerska O.O. 2013*).

More and more scientists are paying attention to the fact that electromyography analysis allows us to make conclusions on the reconstruction of the masticatory and facial muscles, to monitor them in the dynamics of treatment. It is established that recurrences of occlusal anomalies occur with insufficient functional reconstruction of the masticatory muscles. (*Persyn L.S. 2007; Liakhovska A.V. 2015*).

Anomalies, deformities, as well as dentition defects of the dento-maxillaire system prevent from the normal articulation of sounds, contribute to the enrooting of habits of incorrect pronunciation of sounds, the formation of specific bad habits (putting the tongue in the defect and biting the upper lip), which leads to complicated correction and treatment (*Flis P.S. and oth. 2018*).

It is established that an untimely prosthetics or its absence often leads to complications in the form of secondary dento-maxillaire deformities, functional and other disorders,

which requires long-term and costly treatment. The absence of teeth in children contributes to impaired masticatory efficiency, the formation of dysfunction of the temporomandibular joints and tongue, it especially affects the aesthetics of the face, which together often has a negative impact on the child's psyche, forming their social maladjustment (*Doroshenko S.I. 2017, Bida O.V. 2017, Zajac' O.R., Ozhogan Z.R. 2020*).

In such conditions there is a need for prosthetics of teeth and dentitions in the period of temporary and early mixed occlusion, using prosthetic designs that have a positive effect on the normal development of the body as a whole and the dento-maxillaire system in particular (*Drogomyrecka M.S. 2016, Bul'buk O.V. 2018*).

2. The purpose of the study

To assess the functional state of the masticatory muscles (m.masseter) in children with dentition defects in the frontal area before and after treatment.

3. Materials and methods

47 patients (27 males and 20 females) who applied to the Department of Orthopedic Dentistry and Orthodontics, Private Educational Institution Kyiv Medical University, aged from 6 to 17 years with dentition defects in the frontal area were examined and received orthopedic and orthodontic treatment to conduct and determine the state of the masticatory muscles in children with dentition defects. The control group consisted of 27 children who did not have dentition defects and concomitant orthodontic pathology.

All the children were divided into two clinical groups depending on the period of formation of the dento-maxillaire system: I group – children with the mixed period of occlusion, and II group – with the permanent period of occlusion. Each of the groups was divided into two subgroups depending on the method of treatment of orthodontic pathology and the way of fixation of the orthodontic appliance in the oral cavity. The children of group I A (14 people) and II A (8 people) were treated using removable orthodontic prosthesis appliances, whereas the children of group I B (13 people) and II B (12 people) – using non-removable orthodontic appliance. The data on the age and gender distribution of children is presented in Table 1. The functional state of the masticatory muscles was determined in the patients of group I and II using the method of functional electromyography which is registration of bioelectric potentials of muscles before the beginning of treatment and after orthodontic correction of the dimensions of dental arches and restoration of the dentition defect.

All the electromyographic recordings, which were obtained from two symmetrical sections of the masticatory muscles of the right and left sides were performed using an electromyograph M-Test-4, produced by NVP "DH-systemy" (Ukraine), combined into one unit with a personal computer. The studies were performed according to the generally accepted method and with the help of skin electrodes with a permanent inter-electrode distance.

The clinical examination consisted of studying the anamnestic data, identifying bad habits, determining the cause of teeth loss and the age of the dentition defect. During the intraoral examination, attention was paid to the number of teeth, their position in the dental arch, the shape and ratio of dental arches, the ratio of the first permanent molars. Supplementary research methods included the measurement of control and diagnostic models (the transverse dimensions of dental arches were measured by Pont's methods) and the registration of masticatory muscle biopotentials in children.

Table 1

Distribution of the admitted for treatment people by age and gender

Group	Gender				Total number	
	Boys		Girls			
	Absolute number	%	Absolute number	%	Absolute number	%
I A	8	17,02	6	12,76	14	29,78
I B	5	10,63	8	17,02	13	27,65
II A	4	8,51	4	8,51	8	17,02
II B	7	14,89	5	10,63	12	25,53

Statistical processing of the obtained results was performed on a personal computer using the statistical software package “Statistica 6.0” and “Microsoft Excel 2002”, using generally accepted methods of variation statistics (parametric and non-parametric). During the processing of the results by the parametric method, the arithmetic value of the variation series (M), the standard deviation (σ) and the average inaccuracy (m) were calculated. The accuracy of the different was determined using the T-test method (t).

Results: Assessing the results of the replacement of dentition defects by prosthesis appliances for children and correction of the width of dental arches in the transverse plane, we proceeded from the indicators of the physiological norm. In the control group bioelectric activity of the resting lower jaw was recorded in the form of a “straight line”, with maximum jaw compression – the inclusion of motor units, which was presented in the form of high-amplitude oscillations of bioelectric potentials. In turn, relaxation was characterized by a rapid transition to the resting state. The sequence of biopotentials of activity and resting, as well as the change of the sides of chewing in the course of one period was noted at voluntary chewing.

Table 2

The average electromyographic indicators in the control group compared with the patients of groups I and II of the study

Parameters	Masticatory muscle	Control group	Before treatment			
			I		II	
			A	B	A	B
Average compression amplitude (μV)	Right	527 \pm 2,7	386 \pm 6,7•	375 \pm 8,3•	394 \pm 7,4•	384 \pm 6,0•
	Left	486 \pm 11,2	392 \pm 9,5•	378 \pm 10,5•	396 \pm 9,3•	391 \pm 8,7•
Average chewing amplitude (μV)	Right	538 \pm 13,2	402 \pm 9,3•	413 \pm 9,5•	385 \pm 9,2•	425 \pm 8,4•
	Left	529 \pm 14,4	387 \pm 10,4•	423 \pm 8,3•	398 \pm 8,6•	398 \pm 9,4•
Duration of the activity phase (ms)	Right	272 \pm 10,7	337 \pm 9,7•	340 \pm 7,8•	364 \pm 7,4•	327 \pm 9,1•
	Left	293 \pm 13,9	345 \pm 8,3•	354 \pm 8,8•	355 \pm 8,6•	•346 \pm 9,5
Duration of the resting phase (ms)	Right	241 \pm 10,4	284 \pm 13,2•	267 \pm 10,7•	276 \pm 13,2•	295 \pm 11,4•
	Left	252 \pm 12,6	303 \pm 12,7•	289 \pm 9,5•	303 \pm 11,3•	314 \pm 10,5•
Coefficient K	Right	1,01 \pm 0,02	1,28 \pm 0,03•	1,24 \pm 0,02•	1,32 \pm 0,03•	1,25 \pm 0,04•
	Left	1,02 \pm 0,01	1,32 \pm 0,02•	1,26 \pm 0,03•	1,28 \pm 0,05•	1,29 \pm 0,03•

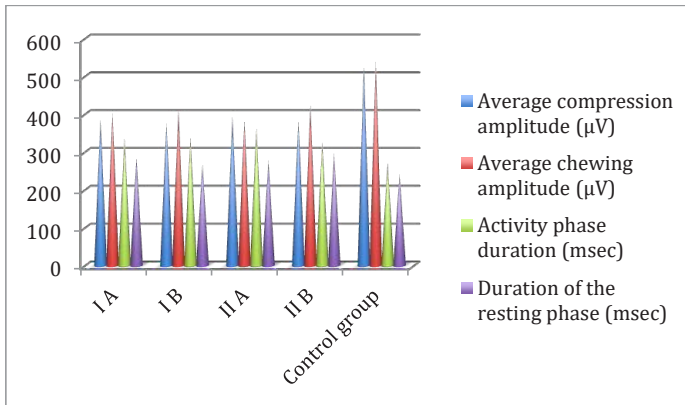
• – accuracy of differences ($p \leq 0,05$) from the indicators of the control group

Analyzing the data presented in Table 2 before treatment, we can observe that representatives of all the study groups had an extension of the chewing period, reducing its rhythm.

The ratios between the excitation and inhibition phases deteriorated with increasing activity phase and decreasing relative bioelectric resting period. The range of the amplitude of biopotentials was decreasing according to standard.

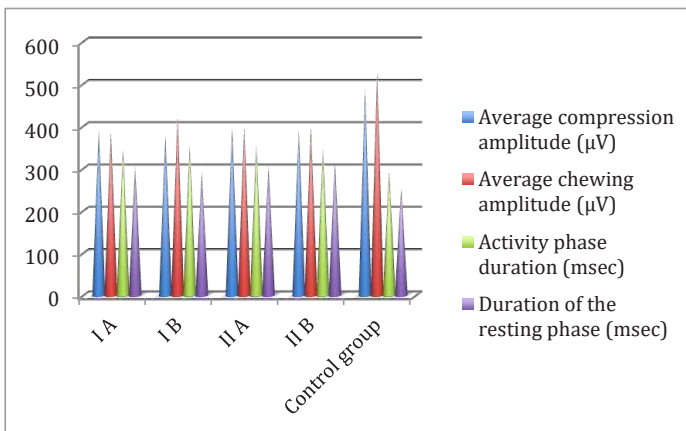
The ratio of the studied groups before the beginning of orthodontic correction and orthopedic replacement of the dentition defect is presented in Diagram 1 for the right masticatory muscle and Diagram 2 for the left one.

Diagram 1



Pic. 1. The ratio of electromyographic examination for the right masticatory muscle before treatment

Diagram 2



Pic. 2. The ratio of electromyographic examination for the left masticatory muscle before treatment

To fix the degree of physiological disorders of the masticatory system in patients with dentition defects in the frontal area and disorders of the dimension of dental arches in the

transverse plane, compared with the control group and the degree of functional rehabilitation of children after correction of the dimension of dental arches and the replacement of the dentition defect we conducted the quantitative analysis of electromyographic indicators in the study groups, the data of which is shown in Table 3.

Table 3

The average indicators of electromyographic indicators in people of the control group compared with the patients of I and II study groups

Parameters	Masticatory muscle	Control group	After treatment			
			I		II	
			A	B	A	B
Average compression amplitude (μV)	Right	527 \pm 2,7	454 \pm 8,6	512 \pm 9,2	417 \pm 9,2	493 \pm 7,4
	Left	486 \pm 11,2	448 \pm 8,9	487 \pm 8,8	415 \pm 8,7	485 \pm 8,3
Average chewing amplitude (μV)	Right	538 \pm 13,2	476 \pm 8,6	517 \pm 12,2	400 \pm 9,2	506 \pm 9,4
	Left	529 \pm 14,4	461 \pm 6,8	503 \pm 11,7	421 \pm 8,9	497 \pm 7,6
Duration of the activity phase (ms)	Right	272 \pm 10,7	305 \pm 9,4	293 \pm 9,7	347 \pm 6,5	286 \pm 8,9
	Left	293 \pm 13,9	309 \pm 8,1	301 \pm 11,1	338 \pm 8,4	302 \pm 9,1
Duration of the resting phase (ms)	Right	241 \pm 10,4	269 \pm 7,5	246 \pm 10,3	289 \pm 11,2	252 \pm 7,6
	Left	252 \pm 12,6	287 \pm 7,9	259 \pm 9,7	303 \pm 10,5	271 \pm 8,2
Coefficient "K"	Right	1,01 \pm 0,02	1,09 \pm 0,04	1,02 \pm 0,02	1,28 \pm 0,05	0,99 \pm 0,01
	Left	1,02 \pm 0,01	1,11 \pm 0,03	1,01 \pm 0,02	1,25 \pm 0,04	1,02 \pm 0,02

• – accuracy of differences ($p \leq 0,05$) from the indicators of the control group

Electromyographic indicators have undergone some changes after orthodontic and orthopedic treatment of children. We would like to state, that before treatment there were observed statistically significant values of electromyograms in children with dentition defects of the frontal area compared with the control group. After treatment, namely, the restoration of the integrity of dentition and correction of the transverse dimensions of dental arches, the data indicates a positive dynamic in treatment, and for some groups – maximum approaching to that of the control group.

The average compression amplitude in children of group I A after treatment was at the level of $454 \pm 8,6 \mu\text{V}$ for the right masticatory muscle and $448 \pm 8,9 \mu\text{V}$ for the left one compared with the control group – $527 \pm 12,7 \mu\text{V}$ and $486 \pm 11,2 \mu\text{V}$, respectively. Duration of the activity phase for the right masticatory muscle – $305 \pm 9,4 \text{ ms}$ and for the left one – $309 \pm 8,1 \text{ ms}$ compared with the control group – $272 \pm 10,7 \text{ ms}$ and $293 \pm 13,9 \text{ ms}$, respectively. The value of coefficient "K" after the replacement of the dentition defect and normalization of the jaws sizes – $1,09 \pm 0,04$ and $1,11 \pm 0,03$. The average compression amplitude in patients of group II B was – $512 \pm 9,2 \mu\text{V}$ та $487 \pm 8,8 \mu\text{V}$ which almost corresponded to the values of the control group – $527 \pm 12,7 \mu\text{V}$ and $486 \pm 11,2 \mu\text{V}$, respectively. Duration of the activity phase was $293 \pm 9,7 \text{ ms}$ and $301 \pm 11,1 \text{ ms}$, compared with the control group – $272 \pm 10,7 \text{ ms}$ and $293 \pm 13,9 \text{ ms}$ for the right and left muscles. The indicator of coefficient "K" after treatment was $1,02 \pm 0,02$ for the right and $1,01 \pm 0,02$ for the left masticatory muscle.

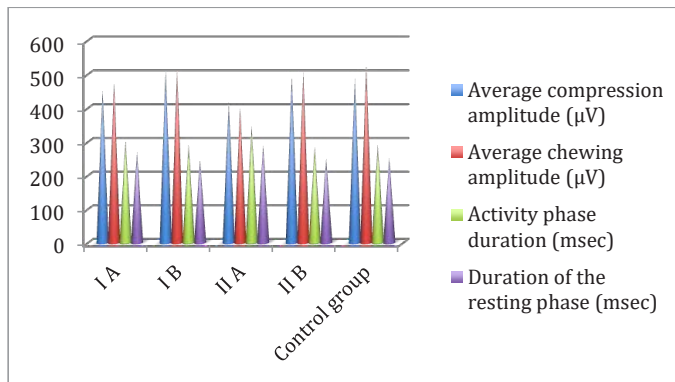
When comparing the indicators between groups I A and I B, we can say that there were identified more qualitative and dynamic changes in electromyographic indicators in group I B than in group I A. The value of coefficient "K" after treatment in children of group II A was at the level of $1,09 \pm 0,04$ and $1,11 \pm 0,03$ and for group I B $1,02 \pm 0,02$ and $1,01 \pm 0,02$ compared

with the control group – $1,01 \pm 0,02$ and $1,02 \pm 0,01$ respectively for the right and left masticatory muscle.

Comparing the data after orthodontic and orthopedic treatment of children of group II, we can say that the qualitative and quantitative electromyographic indicator of for group II B were better than the same indicators for children of group II A. This can be explained by the structural elements that were used in the appliances for each of the subgroups.

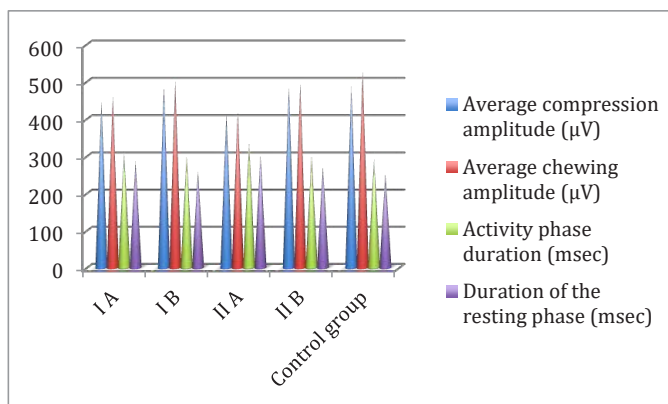
The ratios of the study groups after orthodontic correction and orthopedic replacement of the dentition defect are presented in Diagram 3 for the right masticatory muscle and Diagram 4 for the left one.

Diagram 3



Pic. 3. The ratio of electromyographic study for the right masticatory muscle after treatment

Diagram 4



Pic. 4. The ratio of electromyographic study for the left masticatory muscle after treatment

Analyzing the indicators of patients in the study groups after restoring the integrity of the dentition and correction of the transverse sizes of the dentition, we can state the fact that all the studied indicators improved, but the patients in groups I B and II B had better changes than in groups I A and II A, which is explained by the method of fixation of the appliance in the oral cavity.

Conclusions: When identifying the indicators of bioelectrical activity of the masticatory muscles in children before orthodontic correction and the replacement of the dentition defect of the frontal area compared with the control group, we observed extension of the chewing period, the ratio between excitation and inhibition processes in the masticatory muscles deteriorated by reducing the period of bioelectric resting.

In the case of a timely compensation of dentition defects and restoration of the transverse dimensions of dental arches, the indicators of bioelectrical activity of the masticatory muscles in the group in which treatment was performed with non-removable orthodontic appliances had no statistically significant differences from the standard indicating functional rehabilitation. In children who were treated with removable appliances, these indicators improved, but remained at a worse level than in those treated with non-removable appliances.

References

- Bida O.V., Ozhohan Z.R. (2017) *Osoblyvosti ortodontychnoho likuvannia zuboshchelepykh deformatsii, obumovlenykh chastkovoju vratoju zubiv, zalezno vid shchilnosti kistkovoju tkanyny shchelep [Peculiarities of orthodontic treatment of dento-maxillaire deformities caused by partial loss of teeth, depending on the density of bone tissue of the jaws]. Innovatsii v stomatologii. Nauk.-prakt. elektron. zhurn. 2017; 3-4(16):30-35 [Ukrainian]*
- Bulbuk O.V., Rozhko M.M., Bulbuk O.I. (2018) *Shliakhy vyboru metodu likuvannia defektiv tverdykh tkanyh zubiv [Ways to choose a method of treating defects in the hard tissues of the teeth] Materialy nauk.-prakt. konferentsii z mizhnarodn. uchastiu "Innovatsiini tekhnologii v suchasni stomatologii", VII stomatologichnyi forum "MEDVIN: stomatologia 2018", m. Ivano-Frankivsk. 22-24 bereznia 2018. 7-18. [Ukrainian]*
- Doroshenko S.I., Yakovchuk V.P. (2017) *Poshyrenist hlybokoho prykusu sered ditei shkylnoho viku ta osnovni etiologichni faktory yoho formuvannia. [Prevalence of deep occlusion among school children and the main etiological factors of its formation]. Novyny stomatologii. 2017; 3:92 [Ukrainian]*
- Drohomyretska M.S., Yakymets A.V., Leporskyi D.V., (2016) *Rezultaty biometrychnoho doslidzhennia patsientiv iz vrodzhenoiu adentiiu lateralnykh riztsiv verkhnoi shchelepy. [Results of biometric examination of patients with congenital adentia of lateral incisors of the upper jaw] Zbirnyk naukovykh prats spivrobotnykiv NMAPO im. P.L. Shupyka – 2016:462-67 [Ukrainian]*
- Flis P.S., Rashchenko N.V., Fylonenko V.V., Melnyk A.A., Etnys L.A. (2018) *Funktsionalnyi stan miaziv zuboshchelepnogo aparatu do ta pislia likuvannia ditei z anomaliami prykusu ta movlennievymy porushenniami. [The functional state of the muscles of the dento-maxillaire system before and after treatment of children with occlusion anomalies and speech disorders] Klinichna stomatologia 2018; 4; 76-83 [Ukrainian]*
- Iezerska O.O., Drohomyretska M.S., Herhel I.M. (2013) *Suchasnyi metod diahnostryki funktsionalnoho stanu SNSShS [Modern method of diagnosing the functional state of the temporomandibular joint]. Visnyk stomatologii 2013;1:183 [Ukrainian]*
- Liakhovska A.V. (2015) *Elektromiografiia zhuvalnykh miaziv u diahnostryki dysfunktsii skro-nevo – nyzhnoshchelepnogo suhlobu u pidlitkiv [Electromyography of the masticatory muscles*

in the diagnosis of temporomandibular joint dysfunction in adolescents]. Visnyk problem biolohii i medytsyny 2015;2(119):165-169 [Ukrainian]

Persyn L.S. (2007) Sovremennyye metody dyahnostyky zubochehlyustno-lytsevukh anomalii. [Modern methods of diagnostics of dento-maxillofacial anomalies] M.,2007:85-95 [Russian]

Rebrova O.Yu. Statystycheskyĭ analiz medytsynskykh dannykh. Prymenenye paketa prykladnykh programm STATISTICA [Fundamentals of statistical analysis. Workshop on statistical methods and research of operations with the use of packages "Statistica", "Excel"]. M: Medya Sfera; 2002. 312 s. [Russian]

Vukolov E.A. Osnovy statystycheskogo analiza. Praktykum po statystycheskym metodam y yssledovanyyu operatsyy s yspolzovanyem paketov "Statistica", "Excel" [Fundamentals of statistical analysis. Workshop on statistical methods and research of operations with the use of packages "Statistica", "Excel"]. M: Forum; 2008. 464 s. [Russian]

Zajac' O.R., Ozhogan Z.R. (2020) Poshyrennist zuboshchelepnykh anomalii u ditei Ivano-Frankivskoi oblasti. [Prevalence of dento-maxillaire anomalies in children of Ivano-Frankivsk region]. Suchasna stomatolohiia. 2020;1:68-72 [Ukrainian]